

# Photobiomodulating Lasers and Children's Dental Care

Lawrence Kotlow, DDS, Albany, New York

*J Laser Dent* 2009;17(3):125-130

## INTRODUCTION

Peer-reviewed, evidenced-based studies describing the benefits of using hard and soft tissue lasers are well documented in the dental literature. The use of the erbium family of lasers,<sup>1</sup> Nd:YAG lasers,<sup>2</sup> diode lasers,<sup>3</sup> carbon dioxide lasers,<sup>4</sup> and argon lasers<sup>5</sup> and are well understood and used around the world.

Photobiomodulating (PBM) lasers are devices that produce energy levels below 0.5 Watt and are not used for invasive surgical procedures.<sup>6-7</sup> PBM lasers do not produce or require temperature elevation in a target tissue (i.e., photothermal effects), but rather create a photobiomodulation effect within the target tissue. The benefits and usage of these lasers are gaining acceptance within the dental community and are often identified by different names. The most common descriptions are cold lasers, healing lasers, and low-level laser therapy (LLLT).<sup>8</sup> The beneficial effects are described as a photobiological or photochemical effect on the target tissue.<sup>9-10</sup> Low-level lasers produce energy in a range of 50-500 milliwatts (mW). PBM lasers produce a stimulation and/or suppression of biological processes and allow the tissue to generate an intracellular or biological response. The present body of knowledge of PBM suggests that one of the major effects is created within the cell mitochondria and results in an increase the cell's fuel for energy and repair, or adenosine triphosphate (ATP).<sup>8, 10-11</sup>

PBM lasers are often semiconductor diode lasers. The author is familiar with two general types: one,

consisting of InGaAlP (Indium-Gallium-Aluminum-Phosphide) in the visible light range of 630 to 680 nm; and two, GaAlAs (Gallium-Aluminum-Arsenide) in the invisible range of 750 to 910 nm. Other wavelengths can also be used.<sup>12</sup> PBM lasers affect damaged cells and do not produce harmful or negative effects on healthy cells.

The U.S. Food and Drug Administration (FDA) categorizes photobiomodulating lasers as posing no significant risk (NSR) and therefore these devices are considered safe. In the medical community, the FDA has given marketing clearance for such procedures as pain control and carpal tunnel syndrome treatment. At this time, all dental applications should be considered *off-label* usage in the United States. Essentially, this means that there is no 'indication for use' statement in the operating manual. (For more information on regulatory approval, please refer to Sulewski JG. Clearing the FDA hurdle, from initial device application through regulatory approval to the clinical operator: An update on dental laser marketing clearances, *J Laser Dent* 17(2):81-86.) In spite of the NSR designation, the author avoids using PBM lasers on patients who are pregnant or who have malignancies.

There are three types of effects of photobiomodulating laser therapy: a primary local event which is simply absorption of the light directly by the cellular chromophores or cytochromes; and secondary changes induced by cells that have absorbed photons which initiate cell-specific responses such as increased cell metabolism and blood circulation. These beneficial

## ABSTRACT

Many laser instruments are available for treating oral disease. Some treatments involve removal of hard and/or soft dental tissue. However, other beneficial therapeutic results can occur without a photothermal event, and these effects are known as photobiomodulating or low-level laser effects. They can be produced by all lasers; however, specific photobiomodulating laser instruments are available that operate at levels below 500 mW and can be used to provide a wide range of benefits. This article will describe the many uses for these devices used in the author's pediatric dental practice.

effects can occur in areas of the body not being directly irradiated.<sup>12</sup>

It should be mentioned that there is some controversy in the scientific community about PBM effects;<sup>13-14</sup> however, more than 2500 articles have been written and accepted.

The effects produced by nonsurgical lasers are not limited to low-level lasers. Hard and soft tissue lasers, which are used for surgical procedures, also are capable of producing beneficial PBM effects when used in noncontact, defocused modes. Thus at low energy output levels (less than 500 mW) they do not appear to produce heat build-up within the irradiated tissue. Examples of PBM effects that may be attributed to the nonthermal effect of hard and soft tissue lasers are treatment of postsurgical discomfort; treatment of postsurgical or acute infection, pain, and swelling due to trauma; and maintaining vitality of injured teeth.<sup>15</sup>

PBM devices may consist of a nonlaser cluster of light-emitting diodes (LEDs) of various wavelengths or may be a single wavelength laser probe emitting at 660, 808, or 830 nm. Examples of both such devices as used by the author are shown in the accompanying table. Typically the cluster type used for treatment provides between 4 to 12 Joules (J) per minute externally, and intraoral probes provide between 2 to 8 J per minute.

**PBM USES IN TREATMENT OF PEDIATRIC PATIENTS**

**1. Reduction of pain and creation of an analgesic effect during restorative dental procedures**

The capability to produce an analgesic effect allows PBM devices to reduce and often eliminate the need for a local anesthetic during restorative dental procedures. A tooth being treated is not numb, however the ability of the body to recognize or feel pain appears to be significantly reduced.<sup>16</sup> Teeth exposed to laser therapy have lower levels of pain as compared to those with the placebo treatment. A photobiomodulating effect can be accomplished by using PBM lasers that are limited to low-level energy (a 660-nm probe on either the Q1000 or the AcuLASER in a

contact mode) or by using an erbium family laser (2940-nm Er:YAG or 2780-nm Er,Cr:YSGG) in a defocused mode.<sup>17</sup>

To achieve an analgesic effect, the author places the tip of the laser in a defocused mode (noncontact, 1 to 3 mm from the tooth surface) when using a 660-nm probe over the crown of the tooth for 1 to 2 minutes, as shown in Figure 1. When an erbium family laser is used, as depicted in Figure 2, the laser's tip is maintained in a defocused mode in continuous motion. This will prevent production of thermal effects within the tooth. Using this technique, the author has found that it is often possible to complete a cavity preparation with the erbium laser without a need for anesthesia. In most instances, while preparing primary teeth and many permanent teeth, it is possible to also use a high-speed dental handpiece to complete the cavity preparation without causing the patient discomfort. (If the patient has not previously experienced the vibrations of the high-speed or low-speed handpiece, there is no preconceived fear factor.) Regardless of the final restoration, the patient is able to leave the dental office without a numb lip, tongue, or cheek. This is especially important in young children, where the potential for developing a lip or tongue injury due to the child's biting is often a concern.

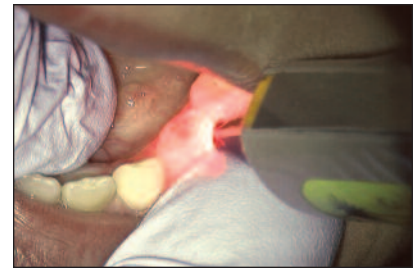


Figure 1: View depicting placement of a PBM laser for tooth analgesia

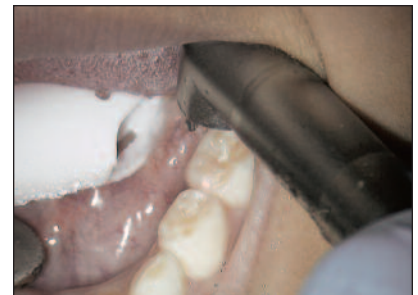

Figure 2: View depicting placement of an Er:YAG laser for tooth analgesia

**2. Treatment of injured anterior primary teeth**

Accidental injuries to maxillary or mandibular anterior primary teeth are quite common in young children. The result of trauma may often result in pulpal death, tooth discoloration, and possibly future infection and damage to developing permanent teeth.<sup>18-19</sup> In untreated teeth, such changes will often occur within 2 to 6 weeks after a child has sustained an injury to the upper incisors. PBM has been shown to be beneficial,<sup>15</sup> and the author has treated infants and toddlers, ranging from 7 months to 5 years of age, with a 660-nm laser probe. After receiving injuries to this area, those patients have had the involved tooth or teeth remain vital. In instances where these teeth were slightly mobile, partially avulsed, or displaced and were treated within 24 to 48 hours after an injury, the teeth demonstrated both clinically and radiographically the ability to remain normal in color, maintain vitality, and remain asymptomatic over three or four years.

Successful treatment consists of

PHOTOBIMODULATING DEVICES			
Model	Manufacturer	Type	Wavelength(s)
AcuLASER	Laserex Technologies, Unley, Australia	LED Cluster	660 nm
Q1000	2035, Inc., Rapid City, S.D., USA	LED Cluster: 8 LEDs/12 diodes	470-940 nm 660-nm probe 808-nm probe
MedX Home Unit	MedX Health Corp., Mississauga, Ontario, Canada	Diode cluster: 9 red diodes and 40 infrared diodes	633 and 880 nm
DioBeam 830	Laser Light Canada, Tottenham, Ontario, Canada	Single Probe	830 nm

placing a PBM laser probe on the facial and palatal area of the traumatized tooth for 1 minute. It may be advantageous, in some instances, to re-treat the affected tooth or teeth similarly at 3- and 5-day intervals after the accident.

Case 1: A child presented who had fallen and partially extruded the maxillary central incisors. The initial radiograph in Figure 3 shows the initial injury. Treatment consisted of repositioning the teeth with manual pressure and then placing the 660-nm laser probe over the labial surface of the crowns and roots for 1 minute each on the facial and lingual aspects for a dosage of approximately 4 J/min. Figure 4 depicts the successful maintenance of the teeth 1 year later.

### 3. Treatment of permanent tooth trauma

Case 2: A 10-year-old female child was seen due to tooth #9 being partially avulsed. A clinical and radiographic examination revealed the tooth was extruded from the tooth socket approximately 5 mm (Figure 5). The tooth was gently repositioned into the

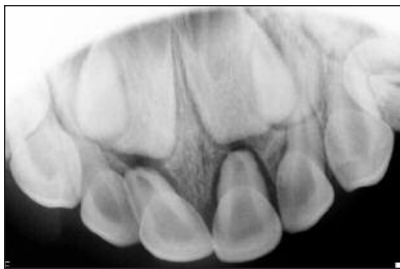

Figure 3: Radiograph of initial injury, with a partial avulsion of the two central incisors

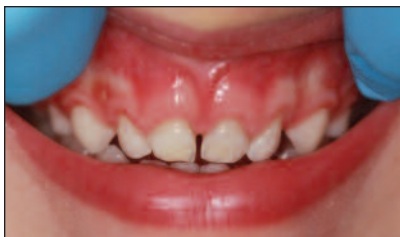

Figure 4: One-year post-treatment view of anterior teeth showing stable dentition and periodontal health

correct position by having the patient slowly bite on a crown seater. Once the tooth appeared to be in correct alignment, it was splinted into place with a band of composite (Figure 6). The tooth was then exposed to the 660-nm probe for 1 minute facially and 1 minute palatally. This procedure was repeated in three days and again at 7 days post-trauma. At the end of 23 months (Figure 7) the tooth remained vital and asymptomatic, both clinically and radiographically.

### 4. Treatment of inability to open the oral cavity due to cellulitis and muscle trismus

Patients seen for emergency visits due to oral infections may have difficulty opening their mouth adequately to allow an accurate examination of the oral cavity, as shown in Figure 8. PBM therapy could provide some relief.<sup>20</sup> This condition may be due to trauma or infection of an abscessed tooth. This lack of access may prevent drainage and relief of pain of an infected tooth. Placing the Q1000 instrument over the affected area in a contact position for three minutes gave the patient enough relief to

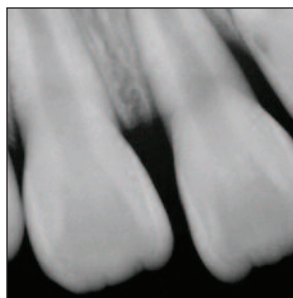


Figure 5: Radiograph of partially avulsed left central incisor

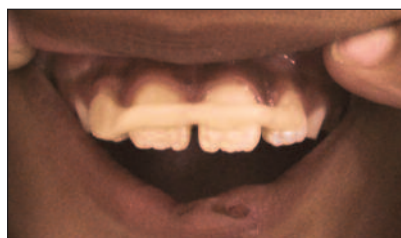

Figure 6: View of composite splint in place

allow for adequate opening and drainage of the infected tooth area.

### 5. Treatment of temporomandibular joint (TMJ) and postorthodontic adjustment discomfort

PBM therapy has been shown to be effective in treatment of TMJ pain<sup>21</sup> as well as for alleviation of discomfort during orthodontic procedures.<sup>22</sup>

Case 3: A 13-year-old female patient presented with a history of morning pain in the areas of both left and right ears. An oral examination revealed many TMJ discomfort signs: ringing in the ears, jaw pain upon chewing and opening her mouth fully. The patient was treated for three visits (using the Q1000 for a 3-minute cycle on the left side and the MedX cluster on the right side), externally over the TMJ areas on alternate days (Figure 9). In addition, the 660-nm laser (2.2 Joules)

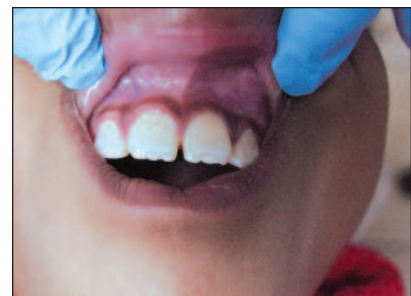

Figure 7: Twenty-three months post-treatment, showing normal tooth alignment and healthy tissue

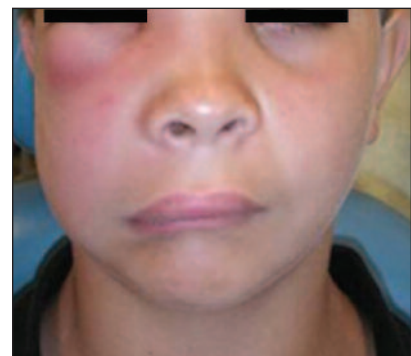

Figure 8: Extraoral view of a typical patient who presents with a severe infection due to pulpitis

was applied intraorally for 1 minute on each trigger point (Figure 10). The patient indicated she felt relief immediately and after 3 days was essentially pain-free.

Figure 11 shows the Q1000 device being used for treatment of post-orthodontic adjustment discomfort.

### 6. Elimination the gag reflex

A simple solution for many gaggers is to place a small dab of salt on the tip of the tongue. Unfortunately, this method does not work on all patients. Stimulation of the acupuncture point on the inside area of the wrists, known as the P6 meridian, can reduce the nausea and gagging sensations.<sup>23-25</sup> The P6 point is positioned on the undersurface of the wrist approximately 1 inch from the wrist crease; this is approximately the width of the distal thumb phalanx. Applying laser energy using 4 Joules of the MedX (either the 633- or 880-nm wavelengths) held in contact, perpendicular to the tissue on the P6 point can often provide sufficient relief to eliminate a gag reflex. Strong gag reflexes prevent the taking of intraoral radiographs, placement of rubber dam, or visualization and treatment of dental caries, especially in the most distal point of upper molars. Such areas may be successfully treated when the PBM laser is placed on the P6 acupuncture point for 1 minute, as shown in Figure 12.

### 7. Treatment of soft tissue injuries

Benefits of pretreatment of surgical sites or post-traumatic soft tissue injuries with the PBM laser include reducing postsurgical pain and allowing the inflammatory response to start earlier.<sup>26-28</sup> These effects are thought to be the result of laser light affecting both the cell membrane and components within the nucleus of the cell. This results in stimulating and accelerating the rate of healing; reducing and resolving tissue inflammation; providing significant pain relief;

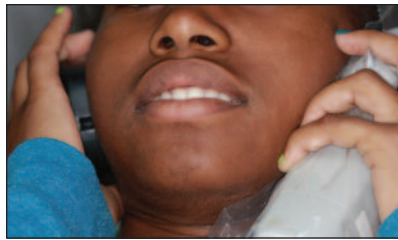

Figure 9: Extraoral treatment of of TMJ condition

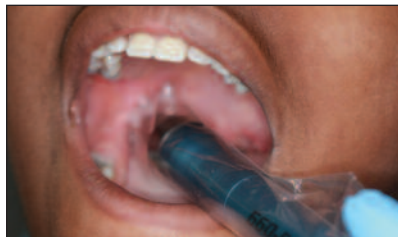

Figure 10: Intraoral treatment of trigger points

improving tensile strength of the wound; and stimulating the immune system to resolve infection. The tertiary effect of irradiating one area of the body and having similar effects manifest elsewhere on other wounds of the body suggests a systemic effect of PBM laser energy.<sup>12</sup> This appears to be a significant reason why it is difficult to create a study using the left and right side of the same patient. The systemic effects prevent the examiner from determining whether there is a difference between a placebo effect and the laser's effect.

Case 4: A 4-year-old boy received an injury to his upper teeth and soft tissue when playing "roller coaster" at home on furniture. The anterior teeth were treated with the DioBeam 830 intraorally at 4 J/min and the MedX cluster laser extraorally at a setting of 3 J/min. This treatment was performed on the initial appointment and again on the following day (Figures 13-16). The patient has been seen for two years following the incident, and the teeth have remained stable without infection.

### 8. Treatment of intraoral lesions

Children presenting with viral stomatitis or herpetic-like lesions

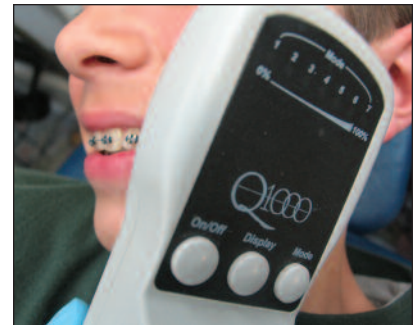

Figure 11: Extraoral treatment of a patient having discomfort with orthodontic treatment. The device is positioned directly over the affected area

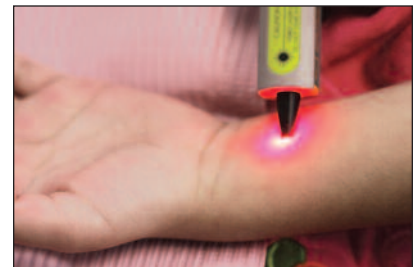


Figure 12: Placement of the laser on the P6 acupuncture point

can benefit from PBM treatment using a variety of devices, especially if the treatment can begin near the first appearance of the problem.<sup>29-33</sup>

Case 5: A 10-year-old patient presented with multiple lesions intraorally and significant discomfort. The Q1000 was placed extraorally for 3 minutes (Figure 17). The patient returned 4 days later with reports of no discomfort and with most of the lesions healed. In the author's experience, since the laser energy scatters through the tissue, some areas may absorb different amounts of that energy and not fully resolve. Those lesions would require additional treatment on a subsequent appointment.

Case 6: As a final example, a surgical laser (DioDent Micro 980®, HOYA ConBio, Fremont, Calif.) was used to treat a child who presented with herpes labialis. For further information, see Kotlow L. Treatment of aphthous ulcers and herpes labialis. *J Laser Dent*

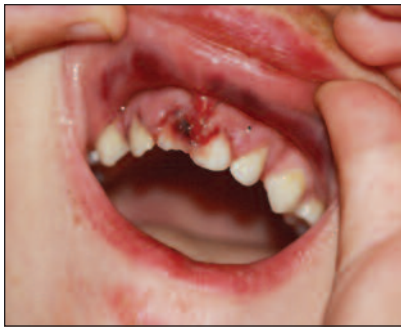

Figure 13: Examination of initial trauma

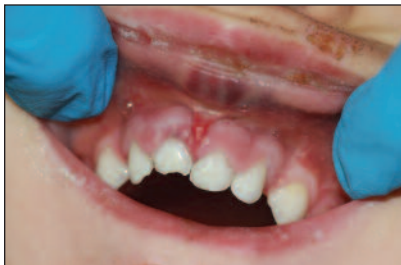

Figure 14: Two days post-treatment

2008;16(Spec. Issue):47-48. Treatment consisted of lasing the entire upper left quadrant for 2 minutes using a defocused tip according to the manufacturer's instruction for this indication for use. The power density is within the parameters of PBM. Figures 18-19 show the perioperative and two-day postoperative views.

**CONCLUSION**

Photobiomodulating lasers provide pediatric dental patients many benefits including reducing the discomfort and pain from surgical sites and injuries; reducing the duration of healing from trauma and soft tissue surgery traumatic injuries; eliminating or reducing the gag reflex and nausea; and relieving muscle discomfort from postorthodontic adjustments. The mechanisms of these benefits are still undergoing investigation and need more scientific studies to allow for proper understanding.

**AUTHOR BIOGRAPHY**

Dr. Lawrence Kotlow has had a private dental practice located in Albany, New York since 1974,

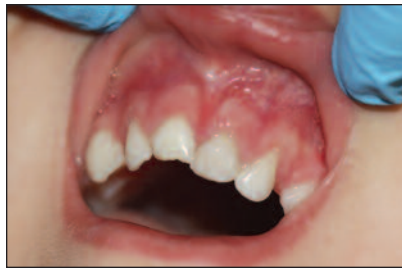

Figure 15: One month post-trauma

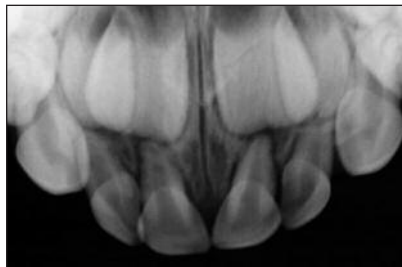

Figure 16: Radiograph one month post-trauma

specializing in Pediatric Dentistry. He is a graduate of the University at Buffalo The State University of New York (SUNY), New York University College School of Dentistry, and the Cincinnati Children's Hospital pediatric dental postgraduate program. He is Board-certified in Pediatric Dentistry. Dr. Kotlow has Advanced Proficiency certification from the Academy of Laser Dentistry in the erbium laser and has Standard Proficiency in the Nd:YAG and diode lasers. He is a Recognized Course Provider for the Academy of Laser Dentistry and has achieved Mastership in the Academy of Laser Dentistry. Dr. Kotlow has published many articles on using the erbium laser in pediatric dentistry and contributed a chapter to the October 2004 edition of *Dental Clinics of North America: Lasers in Clinical Dentistry* entitled "Lasers in Pediatric Dentistry." He has lectured throughout the United States, Canada, Australia, and Taiwan about pediatric dentistry and lasers. Dr. Kotlow may be contacted by e-mail at lkotlow@aol.com.

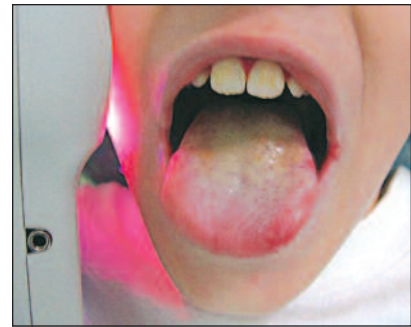

Figure 17: Extraoral laser application

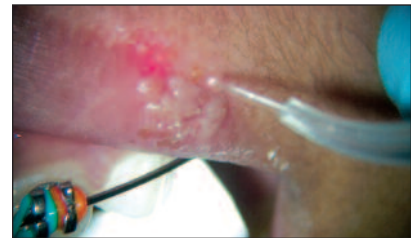

Figure 18: Treatment of herpes labialis with 980-nm surgical diode laser used out of contact. The white tip of an evacuation system is shown in the lower portion of the photograph

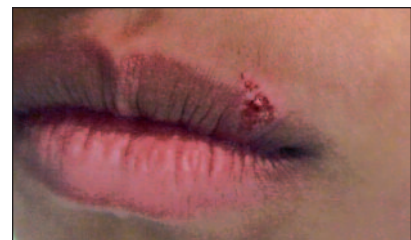

Figure 19: Forty-eight hours post-treatment showing good healing

**Disclosure:** Dr. Kotlow has evaluated and beta-tested new equipment for various dental and laser companies such as Lares, Schick, HOYA ConBio, and Innovative Optics.

**REFERENCES**

1. Kotlow L. The use of the erbium hard & soft tissue laser in the pediatric dental practice. *J Southeast Soc Pediatr Dent* 2001;17:12-14.
2. White JM, Goodis HE, Rose CL. Use of the pulsed Nd:YAG laser for intraoral soft tissue surgery. *Lasers Surg Med* 1991;11(5):455-461.
3. Magid KS, Strauss RA. Laser use for esthetic soft tissue modification. *Dent Clin North Am* 2007;51(2):525-545.

4. Wilder-Smith P, Arrastia A-MA, Liaw L-H, Berns M. Incision properties and thermal effects of three CO<sub>2</sub> lasers in soft tissue. *Oral Surg Med Oral Pathol Oral Radiol Endod* 1995;79(6):685-691.
5. Powell GL, Ellis R, Blankenau RJ, Schouten JR. Evaluation of argon laser and conventional light-cured composites. *J Clin Laser Med Surg* 1995;13(5):315-317.
6. Walsh LJ. The current status of low level laser therapy in dentistry. Part 1. Soft tissue applications. *Aust Dent J* 1997;42(4):247-254.
7. Walsh LJ. The current status of low level laser therapy in dentistry. Part 2. Hard tissue applications. *Aust Dent J* 1997;42(5):302-306.
8. Ross G, Ross A. Low level lasers in dentistry. *Gen Dent* 2008;56(7):629-634.
9. Kotlow L. Lasers and pediatric dental care. *Gen Dent* 2008;56(7):618-627.
10. Sun G, Tunér J. Low-level laser therapy in dentistry. *Dent Clin North Am* 2004;48(4):1061-1076.
11. Corazza AV, Jorge J, Kurachi C, Bagnato VS. Photobiomodulation on the angiogenesis of skin wounds in rats using different light sources. *Photomed Laser Surg* 2007;25(2):102-106.
12. Tunér J, Hode L. *Laser therapy: Clinical practice and scientific background*. Grängesberg, Sweden: Prima Books AB, 2002: Chapter 3 Biostimulation (pp. 61-114) and Chapter 11 The mechanisms (pp. 333-364).
13. Tunér J, Hode L. It's all in the parameters: A critical analysis of some well-known negative studies on low-level laser therapy. *J Clin Laser Med Surg* 1998;16(5):245-248.
14. Tunér J, Hode L. 100 positive double blind studies – Enough or too little? In: Longo L, Hofstetter AG, Pascu M-L, Waidelich WRA, editors. *Laser Florence '99" A window on the laser medicine world*, October 28-31, 1999, Florence, Italy. Proc. SPIE 4166. Bellingham, Wash.: SPIE – The International Society for Optical Engineering, 1999:226-232.
15. Tunér J, Hode L. *Laser therapy: Clinical practice and scientific background*. Grängesberg, Sweden: Prima Books AB, 2002: Chapter 5 Dental laser therapy (pp. 201-238).
16. Whitters CJ, Hall A, Creanor SL, Moseley H, Gilmour WH, Strang R, Saunders WP, Orchardson R. A clinical study of pulsed Nd:YAG laser-induced pulpal analgesia. *J Dent* 1995;23(3):145-150. Erratum in: *J Dent* 1996;24(1-2):151.
17. Genovese MD, Olivi G. Laser in paediatric dentistry: Patient acceptance of hard and soft tissue therapy. *Eur J Paediatr Dent* 2008;9(1):13-17.
18. Fried I, Erickson P. Anterior tooth trauma in the primary dentition: Incidence, classification, treatment methods, and sequelae: A review of the literature. *ASCD J Dent Child* 1995;62(4):256-261.
19. Borum MK, Andreasen JO. Sequelae of trauma to primary maxillary incisors. I. Complications in the primary dentition. *Endod Dent Traumatol* 1998;14(1) 31-44.
20. Tunér J, Hode L. *Laser therapy: Clinical practice and scientific background*. Grängesberg, Sweden: Prima Books AB, 2002: Chapter 4 Medical indications (pp. 115-200).
21. Carvalho CM, de Lacerda JA, dos Santos Neto FP, Cangussu MCT, Marques AMC, Pinheiro ALB. Wave-length effect in temporomandibular joint pain: A clinical experience. *Lasers Med Sci*. Epub 2009 Jun 30. DOI 1007/s10103-009-0695-y.
22. Turhani D, Scheriau M, Kapral D, Benesch T, Jonke E, Bantleon HP. Pain relief by single low-level irradiation in orthodontic patients undergoing fixed appliance therapy. *Am J Orthod Dentofacial Orthop* 2006 Sep;130(3):371-377.
23. Schlager A, Offer T, Baldissera I. Laser stimulation of acupuncture point P6 reduces postoperative vomiting in children undergoing strabismus surgery. *Br J Anaesth* 1998;81(4):529-532.
24. Agarwal A, Bose N, Gaur A, Singh U, Gupta MK, Singh D. Acupressure and ondansetron for postoperative nausea and vomiting after laparoscopic cholecystectomy. *Can J Anesth* 2002;49(6):554-560.
25. Dundee JW, Yang J. Prolongation of the antiemetic action of P6 acupuncture by acupressure in patients having cancer chemotherapy. *J R Soc Med* 1990;83(6):360-362.
26. Mendez TMTV, Pinheiro ALB, Pacheco MTT, Ramalho LMP, Nascimento PM. Assessment of the influence of the dose and wavelength of LLLT on the repair of cutaneous wounds. In: Rechmann P, Fried D, Hennig T, editors. *Lasers in dentistry IX*, January 26-27, 2003, San Jose, Calif. Proc. SPIE 4950. Bellingham, Wash.: SPIE – The International Society for Optical Engineering, 2003:137-143.
27. Simon A. Low level laser therapy for wound healing: An update. IP22 information paper [Internet]. Edmonton, Alberta, Canada: Alberta Heritage Foundation for Medical Research, 2004. [Cited 2010 Jan 2.] 36 p. Available from: [www.ihe.ca/documents/ip22.pdf](http://www.ihe.ca/documents/ip22.pdf).
28. Woodruff LD, Bounkeo JM, Brannon WM, Dawes KS Jr, Barham CD, Waddell DL, Enwemeka CS. The efficacy of laser therapy in wound repair: A meta-analysis of the literature. *Photomed Laser Surg* 2004;22(3):241-247.
29. Toida M, Watanabe F, Goto K, Shibata T. Usefulness of low-level laser for control of painful stomatitis in patients with hand-foot-and-mouth disease. *J Clin Laser Med Surg* 2003;21(6):363-367.
30. Parkins F, O'Toole T, Yancy J. Nd:YAG laser treatment of aphthous and herpetic lesions. *J Dent Res* 1994;73(Spec Issue):190, abstract 705.
31. Colvard M, Kuo P. Managing aphthous ulcers: Laser treatment applied. *J Am Dent Assoc* 1991;122(6):51-53.
32. Convissar RA. Aphthous ulcers and lasers. *Oral Surg Oral Med Oral Pathol Oral Radiol Endod* 1996;82(2):118.
33. Kotlow LA. Pediatric dentistry begins at birth: Lasers and pediatric dental care in treating soft tissue lesions in the dental office. *J Pediatr Dent Care* 2007;13(1):12-16. ■